

Técnicas quirúrgicas

Acta de Otorrinolaringología & Cirugía de Cabeza y Cuello

www.revista.acorl.org.co



Técnicas quirúrgicas

Otoplasty, hybrid technique

Otoplastia, técnica híbrida

Nicolás Heredia-Combariza*, Mauricio Puerta-Romero**, Roxana Cobo***; Jorge Alberto Espinosa****, Diego Andrés Corredor*****, Luis Alberto Solís*****.

- * Otorhinolaryngologist, vice-president of Sociedad Colombiana de Cirugía Plástica Facial y Rinología. Bogota, Colombia. ORCID: <https://orcid.org/0000-0002-7691-1746>
- ** Otorhinolaryngologist and fellow of facial plastic and reconstructive surgery. ORCID: <https://orcid.org/0000-0001-8650-563X>
- *** Otorhinolaryngologist and facial plastic and reconstructive surgeon. ORCID: <https://orcid.org/0000-0002-3658-6256>
- **** Otorhinolaryngologist and facial plastic and reconstructive surgeon. ORCID: <https://orcid.org/0009-0008-7673-586X>
- ***** Otorhinolaryngologist and fellow of facial plastic and reconstructive surgery. ORCID: <https://orcid.org/0009-0005-2415-8763>
- ***** Otorhinolaryngologist and fellow of facial plastic and reconstructive surgery. ORCID: <https://orcid.org/0000-0003-3298-8132>

Cite this article as: Heredia-Combariza N, Puerta-Romero M, Cobo R, Espinosa JA, Corredor DA, Solís LA. Otoplastia, técnica híbrida. Acta otorrinolaringol. cir. cabeza cuello. 2024;52(1): 62-67. DOI.10.37076/acorl.v52i1.748

INFORMACIÓN DEL ARTÍCULO

Historia del artículo:

Recibido: 15 de agosto de 2023

Evaluado: 08 de marzo de 2024

Aceptado: 12 de marzo de 2024

Key words (MeSH):

Ear auricle, surgery, plastic, plastic surgery procedures, Face.

ABSTRACT

Prominauris is one of the most common congenital deformities in the head and neck area and is the principal alteration of the pinna, with a global prevalence of approximately 5%. The leading causes of this anomaly are the abnormal formation of the antihelix or a prominent concha. The surgical techniques in otoplasty can be divided into cartilage-sculpting and cartilage-sparing. Actually, there are multiple surgical techniques described in the literature. The objective of this article is to present a description of a hybrid approach to otoplasty.

Correspondencia:

Dr. Mauricio Puerta-Romero

E-mail: mprotorrino@gmail.com

Address: Clínica Sebastián de Belalcázar, Avenida 4 norte # 7N-53, consultorio 1101, Valle del Cauca, Colombia

Mobile phone: + 57 315 4474744

RESUMEN

Palabras clave (DeCS):

Pabellón auricular, cirugía plástica, procedimiento de cirugía plástica, cara.

La deformidad de orejas en pantalla o *prominauris* es una de las deformidades congénitas más frecuentes en la región de cabeza y cuello y representa la principal alteración del pabellón auricular, lo que afecta aproximadamente al 5 % de la población mundial. Las principales alteraciones que causan esta deformidad son la falta de formación del antihélix o una concha prominente. Las técnicas quirúrgicas de otoplastia se pueden agrupar en dos grandes grupos: las basadas en el uso de suturas y las que consisten en el corte del cartílago del pabellón auricular. En la actualidad existen una gran cantidad de técnicas quirúrgicas descritas en la literatura. El objetivo de este artículo es realizar la descripción de una técnica de otoplastia híbrida.

Introduction

The pinna is a complex structure, mainly composed of skin and cartilage with multiple grooves and convolutions. However, from a surgical perspective, there are five critical structures: the concha, helix, antihelix, tragus, and lobe (1).

The deformity of ear protrusion, or *prominauris*, is one of the most common congenital deformities in the head and neck area and represents the principal alteration of the pinna, affecting approximately 5% of the world's population. It has an autosomal dominant inheritance pattern with variable penetrance (2-4).

The main alterations causing this deformity are lack of formation on the antihelix, deformity in the concha or excess of conchal cartilage greater than 1.5 cm, especially in its posterior wall (3,5,6).

There are multiple surgical techniques that may be divided into two use main instead of bigger groups: the first, in which modifications of the cartilage skeleton are made, making use of sutures; the second, in which cartilage cuts are made, using sutures which can be full- or partial-thickness (1, 3, 6).

The techniques of the first group have the advantage of maintaining the natural contour of the cartilage, requiring less dissection and having a shorter operative time. However, the disadvantage of these techniques is a higher rate of recurrent deformity, especially in stiff cartilages (2).

On the other hand, the second group has the advantage of being able to treat stiffer cartilage, avoid the use of sutures, and decrease the recurrence rate, but has a higher incidence of surface irregularities due to sharp edges, which could leave an abnormal appearance and makes the surgical intervention evident.

cartilage splitting without stitches are based on the phenomenon of interlocking stresses, consisting of the cartilage tending to bend in the opposite direction from the weakened surface (7). The first to apply this concept in otoplasty were Stenström and Chongchet (8, 9).

Given the large number of surgical techniques currently available, the aim of this article is to describe a hybrid otoplasty technique.

The first step to obtain a good surgical result is to make an adequate preoperative diagnosis, for which it is recommended to perform a division by thirds of the pinna, as

shown in **Figure 1**. Frequently, the deformity in the upper third is secondary to poor development of the antihelix; in the middle, it is secondary to a prominent concha, and in the lower third, to a helix tail (cauda helicis) or a prominent lobe.

In order to perform a proper diagnosis, it is also important to know the anthropometric measurements of the pinna. The average height is from 6 to 5.5 cm and the width is 50% to 60% of the height; the distance from the mastoid to helix in the upper part is from 10 to 12 mm; in the middle part, it is 16 to 18 mm; in the lower part, it is 20 to 22 mm; and, finally, the conchomastoid and concha-scaploid angles are 90 degrees, and the auriculocephalic angle is between 25 and 35 degrees Figure 2A-C (6).



Figure 1. Division of the pinna by thirds: The upper third of the superior border of the helix to the root of the helix, the middle third of the root of the antihelix to the intertragic notch and, finally, the lower third from the intertragic fissure to the inferior border of the lobe. Source: Image elaborated by Dr. Mauricio Puerta Romero.

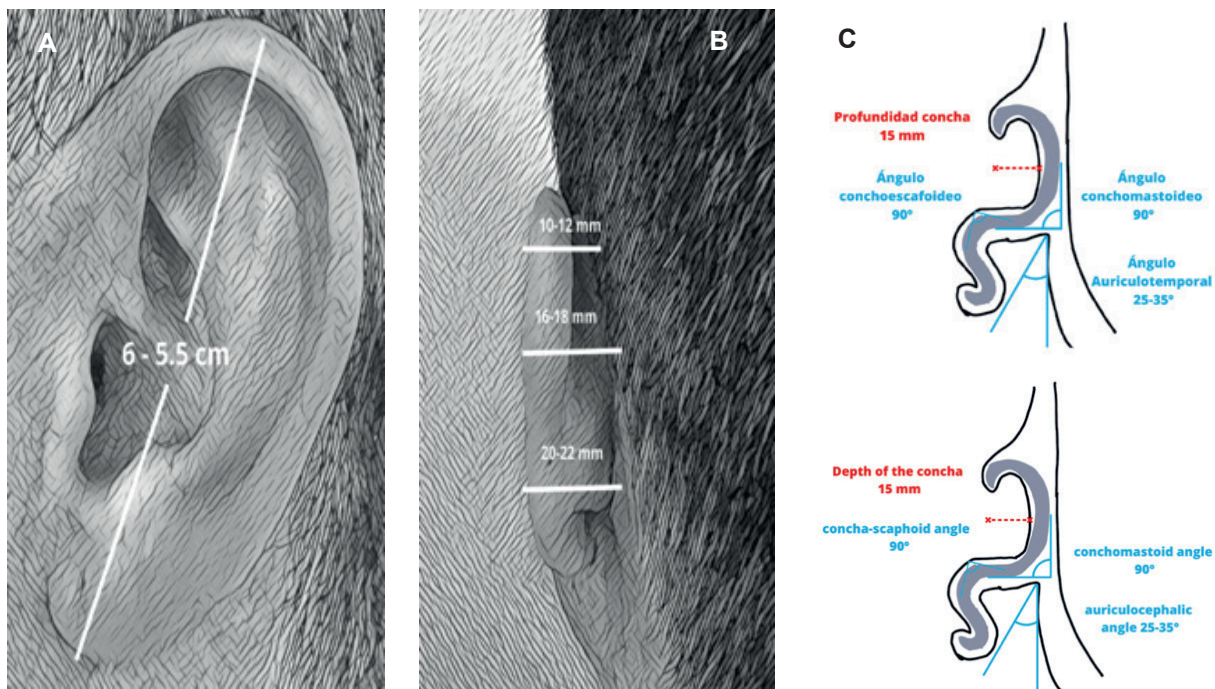


Figure 2. Anthropometric measurements of the pinna. A. Vertical dimension of the pinna ranging from 6-5.5 cm. B. Helix to mastoid distance at the level of the fossa triangularis of 10 to 12 mm; at the level of the concha cymba of 16 to 18 mm, and at the level of the concha cavum of 20 to 22 mm. C. Normal angles of the pinna: conchomastoid of 90°, concha-scapoid of 90°, and auriculocephalic of 24° to 35°. Source: Image elaborated by Dr. Mauricio Puerta Romero.

Surgical technique

The surgical technique starts with the anterior marking of the antihelix, the anterior incision at the level of the internal border of the helix and the posterior skin ellipse. After that, infiltration with lidocaine 2% with epinephrine (1:200000) is performed in the anterior side of the antihelix and in the retroauricular portion; in the case of performing the procedure under local anesthesia, it is recommended to block the auriculo-

temporal and greater auricular nerves, and the auricular branch of the vagus nerve (Figure 3).

Consecutively, the skin incision is then made at the level of the internal fold of the helix, centered on the superior branch of the antihelix, followed by a blunt dissection over the cartilage in this area. The next step is to make partial-thickness incisions in the anterior face of the cartilage in a “grid” fashion with a number 15 scalpel over the new antihelix; additionally, the cartilage can be further weakened with a rasp in order to reduce resistance to deformation (10).

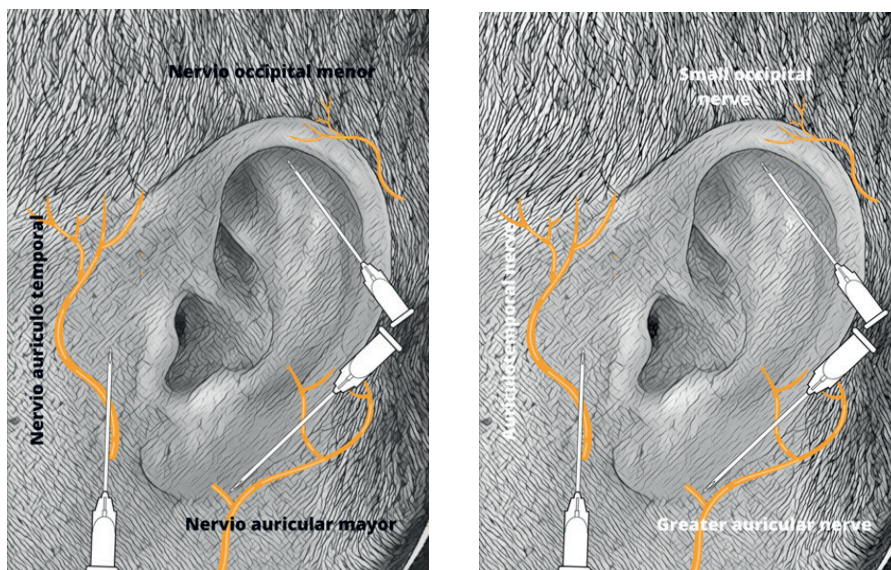


Figure 3. Blocking points for pinna nerves. Source: Image elaborated by Dr. Mauricio Puerta Romero.

Once the work of weakening the anterior side of the cartilage is finished, the incision and posterior resection of the skin in the form of an ellipse at the level of the antihelix and the concha are performed. It is recommended to separate the borders of the incision to reduce tension at the time of closure and reduce the risk of abnormal, hypertrophic, or keloid scarring.

In the event that the patient has a prominent concha – posterior wall with a height greater than 15 mm–, a wedge resection of this wall in the form of an ellipse must be performed, preserving a superior margin of approximately 2 mm to avoid deformities at the level of the antihelix. A recommendation in this step is to dissect the anterior skin at the level of the concha to avoid unwanted skin creases when approximating the cartilage edges with 4-0 polypropylene.

Occasionally, the conchomastoid angle is greater than 90°, and correction of this deformity must be performed with conchomastoid sutures, initially described by Furnas (6). To perform these sutures, a posterior dissection must be made up to the periosteum, in the mastoid region, and anchoring sutures should be made from the fossa triangularis, concha cymba, and concha cavum to the mastoid periosteum with 4-0 polypropylene.

Lastly, the posterior incision is closed with 4-0 polypropylene with horizontal and simple mattress stitches, and an anterior incision with 4-0 polypropylene (**Video 1**).

The most frequent complication of this surgery is postoperative hematoma, so it is essential to check hemostasis before closing the incisions and perform a Bolster dressing at the level of the scapha and concha with laminated alcohol and fixed alcohol with 2-0 silk. Furthermore, it is recommended to leave a compressive bandage with gauze and a Coban™ elastic bandage (11).



Video 1. Step-by-step of the hybrid otoplasty technique. Source:

Figure 4 shows the results obtained with the technique described above in a male patient with poor formation of the antihelix and a prominent concha.

Discussion

The classic objectives of otoplasty were described by McDowell in 1968 and are as follows:

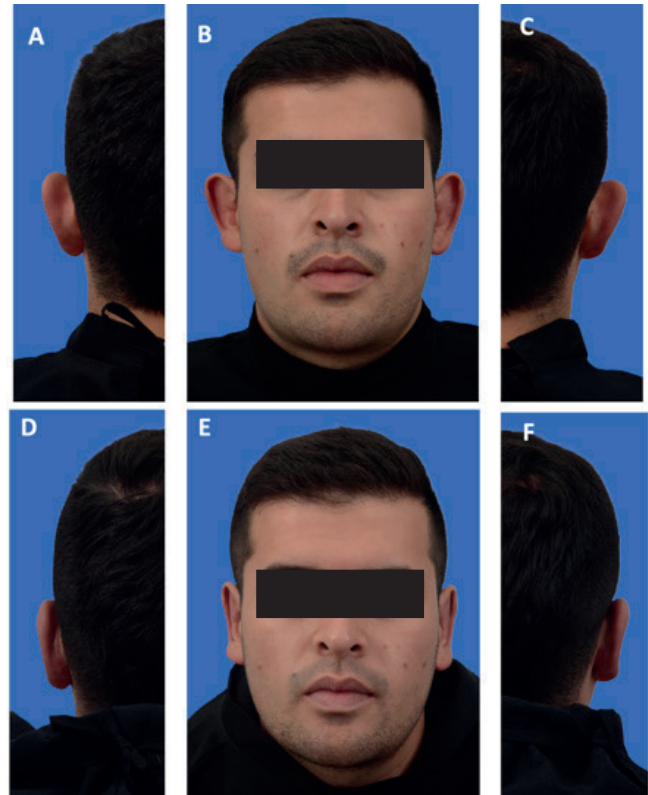

Figure 4. A-C. Preoperative photographs. D-F. Postoperative photographs. Source: Images of a patient of Dr. Nicolás Heredia (main author of the article).

- Any protrusion of the upper third should be corrected;
- The helix should be seen behind the antihelix in the frontal view;
- The helix must have a regular, smooth contour;
- The postauricular sulcus should not be markedly diminished;
- The distance between the helix and the mastoid should be 10 to 12 mm in the upper third, 16 to 18 mm in the middle third, and 20 to 22 mm in the lower third;
- The position of the lateral border of the pinna with respect to the skull should not vary more than 3 mm between the right and left sides (3, 6).

Other factors that must be considered to obtain satisfactory aesthetic results are the position of the retroauricular incision so that the final scar is camouflaged in the retroauricular sulcus, creating an antihelix with a soft and smooth contour, reducing the size of the concha when indicated, and controlling the position of the lobe (12).

By performing the technique described above, these objectives can be met to obtain good results, as shown in **Figure 5**.

As in all surgery, in otoplasty, a good diagnosis and understanding of the anatomy are essential to effectively correct a patient's problem. The main objective is to obtain a natural looking pinna with acceptable protrusion and symmetry (1, 12).

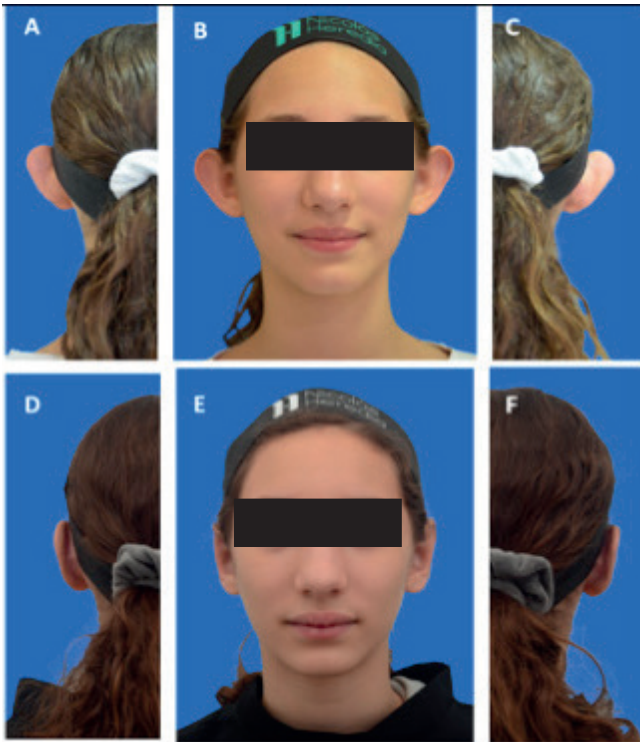


Figure 5. A-C. Preoperative photographs. D-F. Postoperative photographs. Source: Images of a patient of Dr. Nicolás Heredia (main author of the article).

Nowadays, there are more than 170 surgical techniques of aesthetic otoplasty described in the literature, which consist, mainly, of multiple combinations between cartilage resection and preservation techniques. Hybrid techniques that combine both types of approaches may have better aesthetic outcomes, since by making partial-thickness cuts in the cartilage, they decrease the resistance of cartilage to deformation and, consequently, reduce the recurrence rate; however, as they are not complete cuts, there is a lower risk of contour irregularities (1, 12).

The hybrid technique described by the main author allows for significant changes in the shape and position of the pinna, using principles of cartilage resection and suturing techniques in order to optimize the aesthetic results of the surgery. In addition, if necessary, revisions of this technique can be easily performed because it is not a cartilage-destructive technique (2).

Likewise, it has another advantage because it does use the Stenström principle with the cartilage splitting of the anterior surface of the pinna cartilage, and no sutures are used at the level of the cartilage to recreate the antihelix, which avoids the complications associated with the extrusion of stitches in this area, which is frequent (13).

Conclusions

One of the limitations of this work is that it is a descriptive study of the surgical technique that the main author, Dr.

Nicolás Heredia, has developed during his medical practice. Nevertheless, in order to objectively assess the efficacy of the procedure and its reproducibility in the hands of other surgeons, it would be necessary to carry out experimental studies.

Because in the studies of surgical interventions it is difficult to perform randomized double-blind trials, it is challenging to establish which is the best surgical technique for otoplasty; furthermore, in articles of plastic facial surgery there is a publication bias since good outcomes tend to be published and usually there is an underreporting of complications and suboptimal outcomes.

There is no single surgical technique for otoplasty; however, with the combination of basic techniques used in a proper manner, satisfactory aesthetic results can be achieved in patients with *prominauris*.

Acknowledgements

None

Funding

None

Conflicts of interests

None

Declaration of authorship

We confirm that the manuscript has been read and approved by all named authors and that there are no other persons who satisfied the criteria for authorship but are not listed. We further confirm that the order of authors listed in the manuscript has been approved by all of us.

Ethical considerations

Patients authorized the use of photographs for academic purposes.

REFERENCIAS

1. Sevin K, Sevin A. Otoplasty with Mustarde suture, cartilage rasping, and scratching. *Aesthetic Plast Surg*. 2006;30(4):437-42. doi: 10.1007/s00266-006-0061-4.
2. Gantous A, Tasman AJ, Neves JC. Management of the Prominent Ear. *Facial Plast Surg Clin North Am*. 2018;26(2):181-92. doi: 10.1016/j.fsc.2017.12.010
3. Schneider AL, Sidle DM. Cosmetic Otoplasty. *Facial Plast Surg Clin North Am*. 2018;26(1):19-29. doi: 10.1016/j.fsc.2017.09.004.
4. Davis J. Aesthetic Otoplasty. *Otoplasty*. 1997;7(June):3-23.
5. Maurice PF, Eisbach KJ. Aesthetic otoplasty: wedge excision of a flattened helix to create a helical curl. *Arch Facial Plast Surg*. 2005;7(3):195-97. doi: 10.1001/archfaci.7.3.195.

6. Stewart KJ, Lancerotto L. Surgical Otoplasty: An Evidence-Based Approach to Prominent Ears Correction. *Facial Plast Surg Clin North Am.* 2018;26(1):9-18. doi: 10.1016/j.fsc.2017.09.002.
7. Gibson T, Davis WB. The distortion of autogenous cartilage grafts: Its cause and prevention. *Br J Plast Surg.* 1958;10:257-74. doi: 10.1016/S0007-1226(57)80042-3.
8. Stenstroem SJ. A "natural" technique for correction of congenitally prominent ears. *Plast Reconstr Surg.* 1963;32:509-18.
9. Chongchet V. A method of antihelix reconstruction. *Br J Plast Surg.* 1963;16:268-72. doi: 10.1016/s0007-1226(63)80120-4.
10. Rubino C, Farace F, Figus A, Masia DR. Anterior scoring of the upper helical cartilage as a refinement in aesthetic otoplasty. *Aesthetic Plast Surg.* 2005;29(2):88-94. doi:10.1007/s00266-004-0052-2.
11. Limandjaja GC, Breugem CC, Mink van der Molen AB, Kon M. Complications of otoplasty: a literature review. *J Plast Reconstr Aesthet Surg.* 2009;62(1):19-27. doi: 10.1016/j.bjps.2008.06.043.
12. Paul MD. Otoplasty discussion. *Aesthetic Plast Surg.* 2006;30(4):442. doi: 10.1007/s00266-006-0074-z.
13. Obadia D, Quilichini J, Hunsinger V, Leyder P. Cartilage splitting without stitches: technique and outcomes. *JAMA Facial Plast Surg.* 2013;15(6):428-33. doi: 10.1001/jamafacial.2013.326.